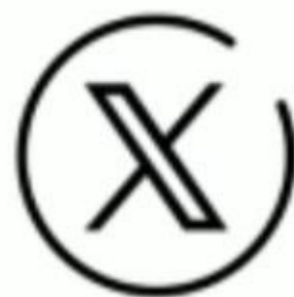

Note

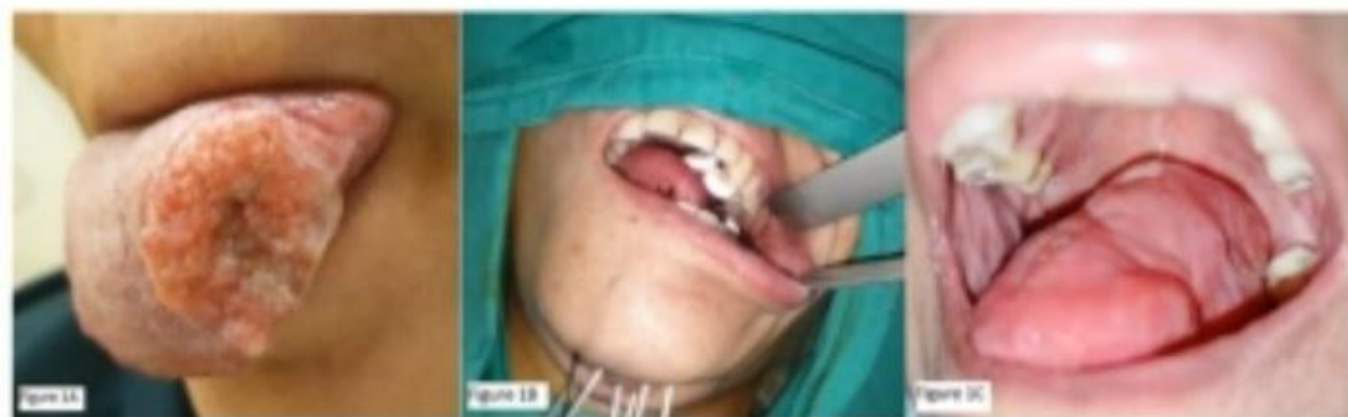Please feel free to photograph and share these slides on social media.



Gokula Kumar Appalanaido
Malaysia

Name: GOKULA KUMAR APPALANAIDO
Institute: UNIVERSITI SAINS MALAYSIA

Hybrid HDRIBT followed by IMRT (HyBIRT) Technique for the Definitive Treatment of Oral Tongue SCC (OTSCC) - First in Human Prospective Study



Acknowledgement:

Malaysian Oncological Society for the travel grant to ESTRO2025

co-authors : Muhamad Yusri Musa, Seng Ewe Ch'ng, Syadwa Abdul Shukor, Siti Noor Fazliah Mohd Noor, Ahmad Fakrurrozi Mohamad, Keerthaanaa Yogabalan, Nor Hafizah Ishak, Francis Hao, Mohd Zahri Abdul Aziz, Nursyatina Abdul Raof, Reduan Abdullah, Jasmin Jalil



Gokula Kumar Appalanaido
Malaysia



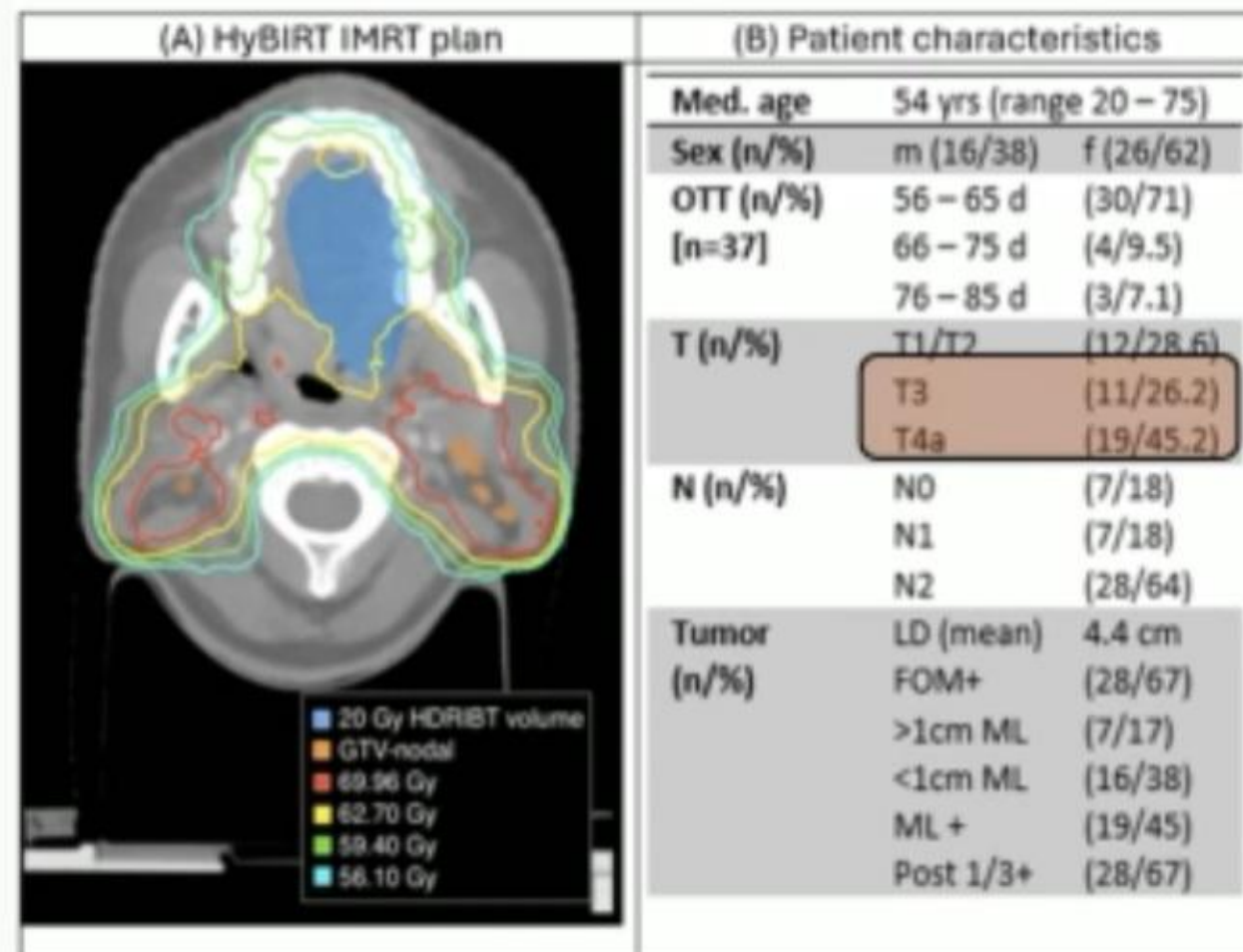
Treatment algorithm & patient characteristics:

Figure 1:

(A) IMRT plan showing 20Gy HDRIBT volume (shaded blue), GTV-nodal (orange), IMRT isodose line: 69.96 Gy (red), 62.7 Gy (yellow), 59.4 Gy (green) and 56.1 Gy (turquoise).

(B) Patient and disease characteristics: OTT; overall treatment time (days), FOM; floor of mouth, d; days, T,N; TNM7 T & N stage, LD; largest dimension, ML+; mid-line; posterior 1/3 tongue involved.

Treatment regimen:

- **HDRIBT** 20Gy in 5F to GTV-P, ensuring 90% of GTV-P receive 25Gy in 5F
- **IMRT** (33 fractions) within 10 days with weekly Cisplatin 40mg/m² x 6 cycles

- Dose:

- 69.96-72.6Gy (gross disease/node),
- 61.71Gy high risk region,
- 56.1y to low risk volume and
- 59.4Gy to the pre-treated HDRIBT field

- EqD2 GTV-P (tongue) >85Gy

- Hard constraint 63Gy to 25Gy HDRIBT volume/isodose line.

This study received institutional human ethics approval (JEPeM Code : USM/JEPeM/21080564)



Gokula Kumar Appalanaido
Malaysia



Study protocol

Inclusion criteria	Exclusion criteria
<ul style="list-style-type: none"> - Tumor with epicentre at anterior 2/3 tongue. - Unable to undergo surgery for various reason/s. - ECOG PS 0-2. - Histologically confirmed SCC. 	<ul style="list-style-type: none"> - Tumor with cortical bone involvement. - Technically not possible to approach the posterior tongue for applicator insertion. - Radiologically confirmed metastatic disease (M1) - Contraindication for nasal intubation.

Follow-up schedule

	Weeks(w), months(m) after IMRT
Clinical assessment <ul style="list-style-type: none"> - Local control - Neck control - Toxicity scoring 	- 0 w, 2w, 6w, 3m, 4m, 5m, then 2 monthly
Imaging:	<ul style="list-style-type: none"> - PET-CT Scan at 3m, repeat at 6m if not CR. - MRI head&neck if clinically indicated thereafter



Gokula Kumar Appalanaido
Malaysia

Results

- Clinical outcome and quality of life of 11 OTSCC patients who underwent HyBIRT technique has been presented as proffered papers in the ESTRO 2023 and ESTRO 2024.
- In this current prospective study, 31 OTSCC patients who refused or unfit for surgery were enrolled from January 2021 till April 2024.
- For statistical analysis, these patients were pooled together with the earlier cohort of 11 patients (n = 42).
- Median follow-up is 17 months (range 1 - 69 months). 10 patients with >36 months f/up.

Treatment outcome:

- At 24 months, 25% of patients had grade 2 (CTC-AE 5.0) periodontal disease, **none needing surgical intervention.**
- Speech and swallowing function vs surgery: **Presented during ESTRO 2024 as proffered paper.**
- **4 patients (not included in this survival analysis) who refused IMRT after HDRIBT or received less than 10 fractions of IMRT recurred at the primary site (in tongue).**

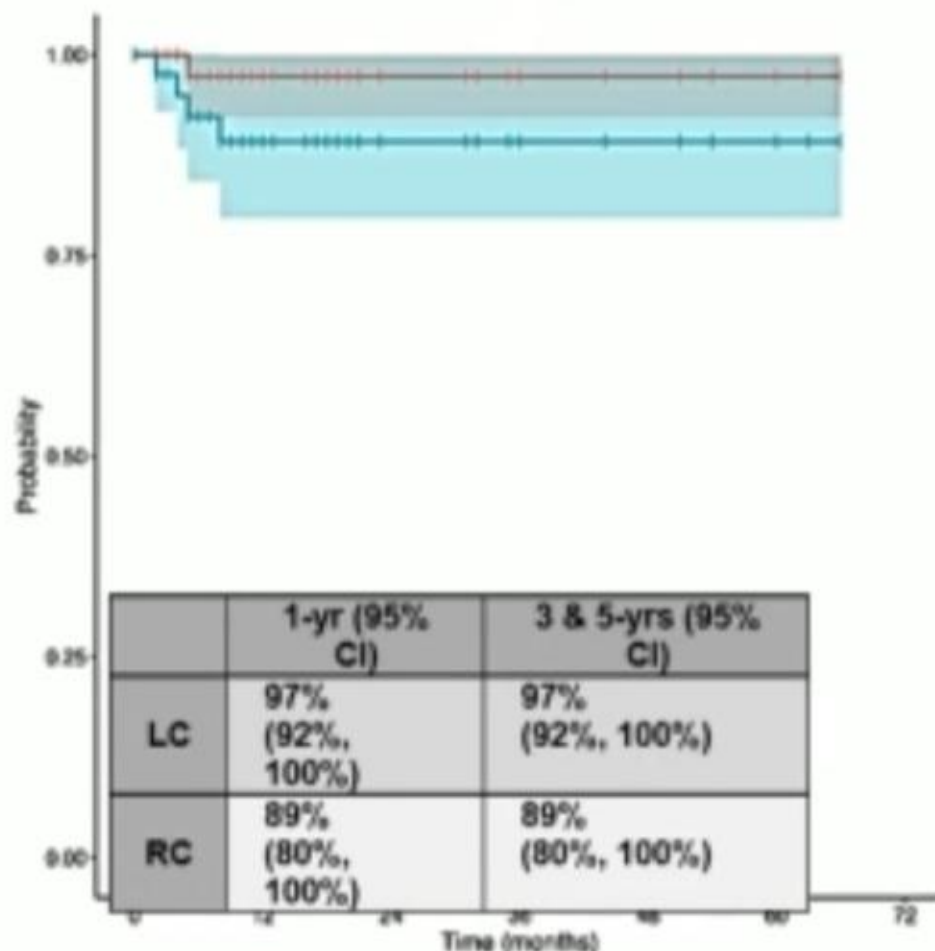


Gokula Kumar Appalanaido
Malaysia

Local (tongue) and regional (neck) control rate

(C) LC and RC plots

Control rates LC RC



Control rates	0	12	24	36	48	60	72
LC	42	22	10	7	5	3	0
RC	42	20	10	7	5	3	0

- One patient died of severe tongue bleed 6 months after treatment (assumed local recurrence)
- 3 patients with TNM7 N2 disease failed in the neck (all had central necrosis of the node in initial radiological scan)
- No patient had skin or dermal lymphatic spread (recurrence). *A.Chaitanya et.al 2021, Dermal metastases in oral cancer after curative treatment: a single institution cohort study.* (reported as 2.83% in surgical serie, ?much higher in real life practice)
- Metabolic CR is seen at primary site by 6 months in all 26 patients with post treatment Pet-CT

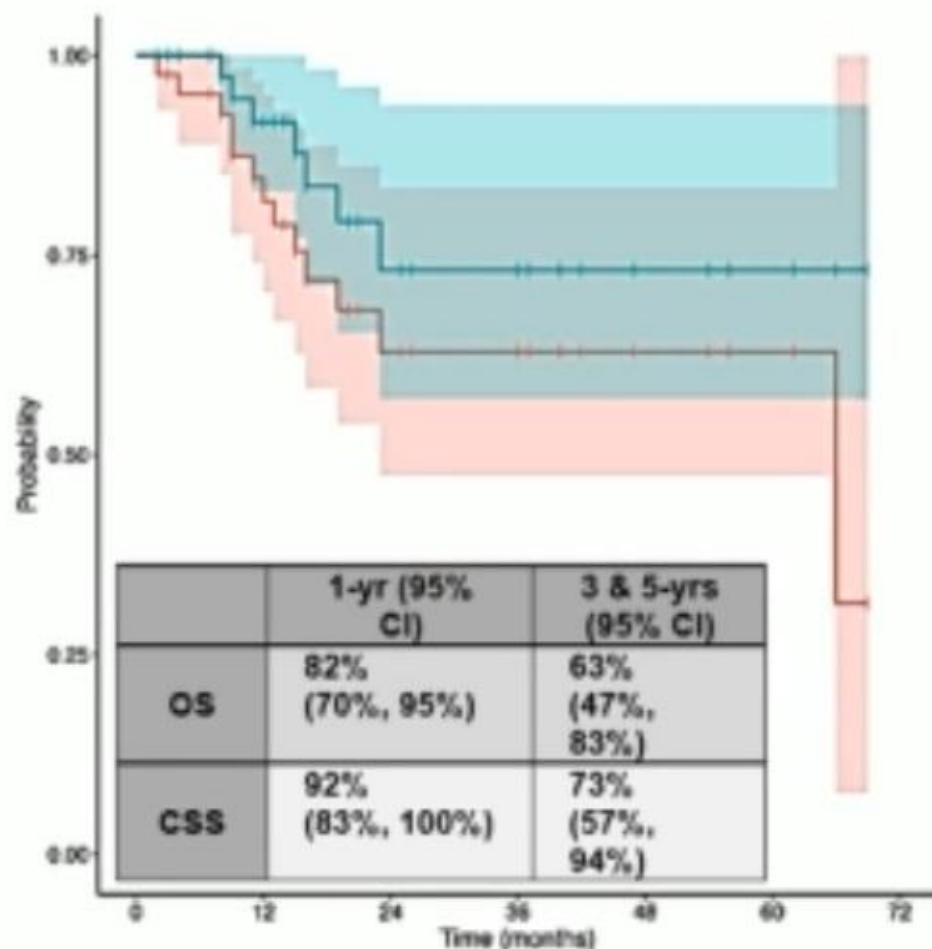
Gokula Kumar Appalanaido
Malaysia

Question

Survival

(A) OS and CSS plots

Survival OS CSS



		Number at risk						
		0	12	24	36	48	60	72
Survival	OS	42	29	12	10	5	3	0
	CSS	42	29	12	10	5	3	0

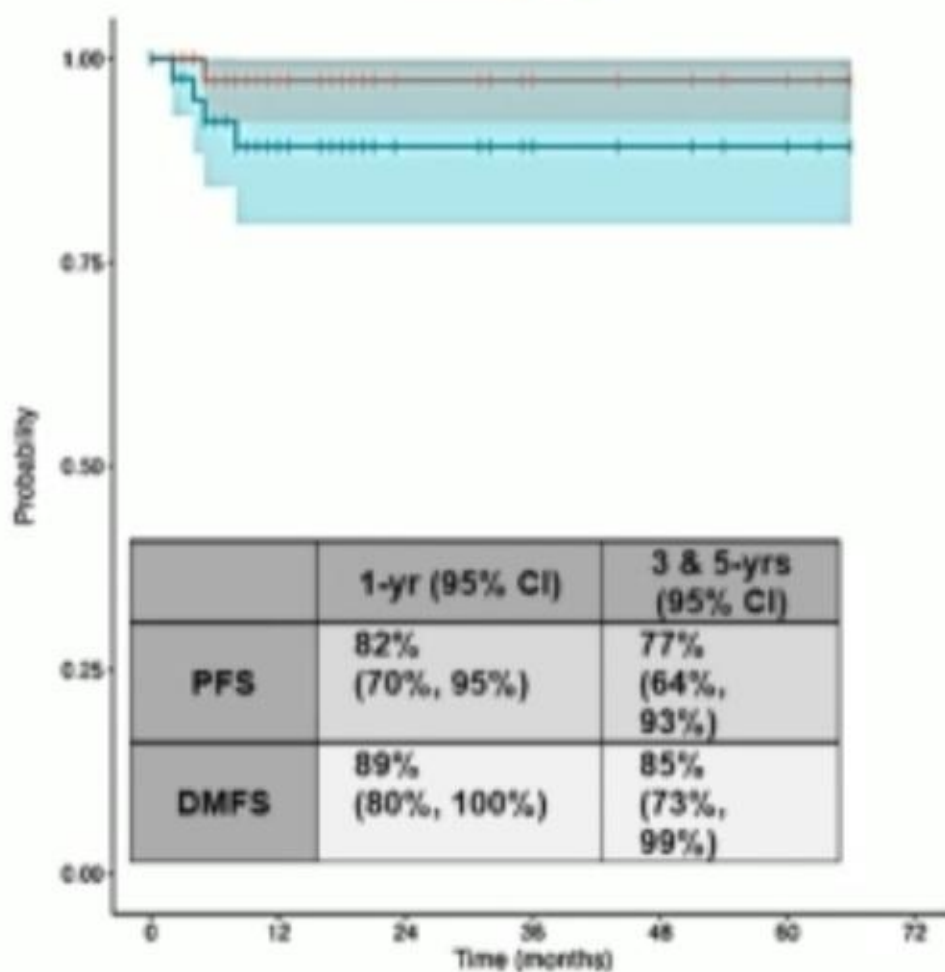
- In the initial cohort of 11 patients, 3 treatment related deaths occurred: cerebral oedema secondary to dehydration, blocked tracheostomy tube in schizophrenic patient and duodenal ulcer bleed due to prolonged steroid use.
- No treatment related deaths in the subsequent 31 prospectively enrolled patients (after the initial learning curve).
- CSS analysis that exclude these 3 patients and other causes of death reflects this (1-year CSS vs OS; 92% vs 82%)

Gokula Kumar Appalanaido
Malaysia

Question

(B) PFS and DMFS plots

Progression PFS DMFS



Number at risk		0	12	24	36	48	60	72
Progression	PFS	42	22	10	7	5	3	0
	DMFS	42	20	10	7	5	3	0

- Interestingly, a very low DM rate is seen in this current study.
- Patients who are without recurrence at the end of 2-years continue to be disease free at 5-years suggesting cure.

(late recurrence is rare)Gokula Kumar Appalanaido
Malaysia

Question

Discussion - historical local/regional control rate of OCSCC

	OCSCC (% total)	Study design	Treatment regimen	Stage	Local/regional control
Soo et al 2005 *Iyer et al 2015	32 (26.9%)	RCT	A1: S → RT A2: dCRT	III - IV	LRRFS: 35% vs 65% (5-year)
Gore et al 2014	45 (43.2%)	RP	A1: S + RT A2: dCRT	I - IV	LC: 70% vs 30% (3-year) LRC: 90% vs 75% (3-year)
Scher et al 2015	73 (100%)	RP	dCRT	87% III - IV	LRC: 37.4% (5-year)
Gokula et al 2024	42 (100%)	P	HyBIRT	71% (T3,T4), 82% (N1,N2)	LC: 97% (5-year) RC: 89% (5-year)



Gokula Kumar Appalanaido
Malaysia



Discussion - historical survival rate of OCSCC

	OCSCC (% total)	Study design	Treatment regimen	Stage	Survival Outcomes
Soo et al 2005 *Iyer et al 2015	32 (26.9%)	RCT	A1: S → RT A2: dCRT	III - IV	DSS: 68% vs 12% (5-yr) DRFS: 92% vs 50%
Spiotto et al 2017	6900 (100%)	RP	A1: S + RT A2: dCRT	III - IVa	OS: 51.8% vs 39.3% (3-yr)
Tangthongkum et al 2017	189 (100%)	RP	A1: S + RT A2: dCRT	III - IVa	OS: 33% vs 24% (5-yr) DSS: 27% vs 25% (5-yr)
Scher et al 2015	73 (100%)	RP	dCRT	87% (III - IV)	OS: 15% (5-yr) DSS: 52%, & 38.1% (1-yr & 3-yr)
Gokula et al 2024	42 (100%)	P	HyBIRT	71% (T3,T4), 82% (N1-N2)	OS: 82% & 63% (1-yr & 5-yr) CSS: 92% & 73% (1-yr & 5-yr)



Gokula Kumar Appalanaido
Malaysia

Hypothesis generating

Promising local and regional control rates due to ?:

- Hybrid radiotherapy regimens of SBRT/HDRIBT + fractionated radiotherapy offer radiobiological benefits (targeting both the high and low α/β ratio tumor cells).
- IMRT after HDRIBT are beneficial in terms of field sterilization from microscopic seedling during HDRIBT.

Low DM rates due to ?:

- Practice of injecting lidocaine into tongue tumor during HDRIBT applicator insertion (*Badwe et.al 2022. Effect of peritumoral infiltration of LA before surgery and survival in BC*)
- Starting chemotherapy within 10 days of HDRIBT “clears” any microscopic dissemination during applicator insertion
- Short anesthesia reducing the risk of hypoxia and distant metastasis (*Rankin et.al 2016, Hypoxic control of metastasis*)



Gokula Kumar Appalanaido
Malaysia



Conclusion

- HyBIRT technique showed a promising clinical outcome in terms of quality of life, local/regional disease control, survival outcome and distant metastatic free survival.
- In our experience, upfront HDRIBT is technically less complex for both implantation and subsequent IMRT radiotherapy planning compared to IMRT followed-by HDRIBT boost.
- While this study included non-metastatic tongue cancer patients of all TNM7 stages, it should be noted that **71% and 82% are TNM7 T3-T4 and N1-N2 disease**, hence the applicability of this technique even in advanced disease.
- Multicentre trial of this HyBIRT technique is needed to confirm the reproducibility of the results.
- HDRIBT and IMRT role in tongue cancer treatment algorithm needs a re-look and our study suggest that this (HyBIRT) organ preservation approach has the potential to become first line treatment.
- **While this is not a RCT, it is Real Life Data.**



Gokula Kumar Appalanaido
Malaysia